



Hate Love Dentures

by John Nosti, DMD,
FAGD, FACE, FICOI

You say you want to increase your production in 2014 and create a niche practice that will stand alone from all of the other practices in your area? Top consultants, practice management gurus and even organizations recommend that dentists map out their continuing education plans and goals in the beginning of the year. Likewise, the New Year often brings out the business man/woman in all of us to budget the year's marketing expenses. If your goals are to add more procedures to your existing patient pool, become more predictable in a procedure that many dentists dislike and to invest a little money marketing in an area very few dentists target – then I challenge you to revisit the art of removable prosthodontics.

It is estimated that 23 million people in the U.S. are fully edentulous, while an additional 15 million are edentulous in one arch.¹ Currently, that is an estimated 61 million complete dentures in the U.S. If 10 percent of these patients have a new denture/dentures fabricated each year and the average dentist charges \$1,400 per denture, this results in an estimated 8.5 billion dollars being spent each year on full dentures. Still think dentures are dead? Consider the fact that the average gross of all Hollywood movies in one year is approximately 9 billion dollars, does targeting full denture patients now seem more worthwhile?

I know what you are saying. "But John, I hate fabricating dentures! The unpredictable fit returned from the lab, the never-

1. Summary Health Statistics for U.S. Adults: National Health Interview Survey, 2009, table 11, 12. U.S. Department of Health and Human Services.

continued on page 64

ending adjustment appointments and, quite frankly, the aesthetics are marginal at best.” In reply, I ask you, besides dental school, what advanced training in removable prosthodontics have you had? Grab a cup of coffee, turn off the TV – let’s get ready to love dentures!

Starting with a Healthy Foundation

If your patient has unhealthy tissue from wearing an old, poor-fitting prosthetic, it would behoove you to begin with a tissue-conditioning process. This could take several weeks. Products like Lynal or Hydrocast work great for this. Start by placing a thin layer of pressure-indicating paste on the inside of one of the dentures, completely covering the intaglio of the denture. Adjust any “show through” spots of acrylic until you have a complete thin layer of PIP. Once this is complete, you are ready to reline the denture(s) with the tissue-conditioning material. When asking the patient to close into occlusion, make sure cotton rolls are used to provide uniform contact on both sides of the denture.

Once the initial set of the tissue conditioner has taken place (follow manufacturers recommendations) it is now time to adjust the occlusion. Verify there are simultaneous, bilateral contacts in MIP and that the occlusion is balanced in excursions. Have the patient return in 48 hours to evaluate the fit of the denture. Where the tissue conditioner is thin or is absent, adjust the denture acrylic there and add more tissue conditioner (the same process you did with the PIP). This may take several visits until the tissue conditioner has a uniform thickness, the denture fits well and the tissue is no longer edematous or erythematous. Once the tissue is healthy, we are ready to begin the new denture process.

First Appointment (approximately 45-60 minutes)

Unlike the denture fabrication process you were taught in dental school, the “Smile Designed Dentures” process requires a little more time on your first visit. Don’t worry, a little extra time spent here will save you plenty of time in the following two visits, as well as reduce your post-op visits. In my experience, this is time well spent! The instruments shown in this article (except the gothic arch tracer) are available in the Removable Smile Design Kit by Ivoclar Vivadent.

Step 1: The Impression

The final impression is considered one of the most important steps in denture fabrication. There are plenty of great impression materials and systems on the market. The Accu-Dent I System (Fig. 1) from Ivoclar Vivadent is an irreversible hydrocolloid that offers a truly hydrophilic impression material. This material must be poured within eight minutes, should not be wrapped in wet paper towels (like you were

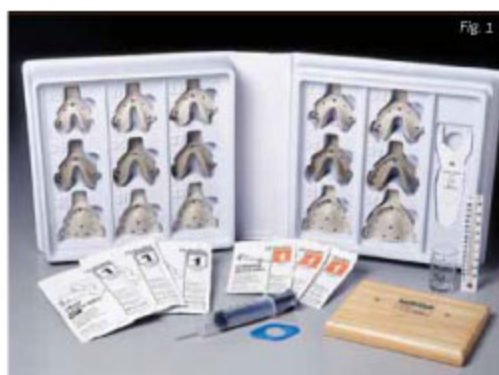

Fig. 1

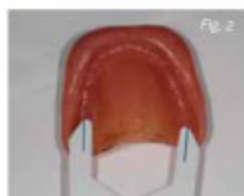

Fig. 2

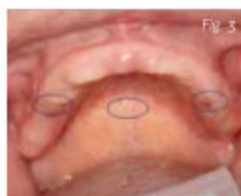

Fig. 3

Fig. 1: Accu-Dent Impression system

Fig. 2: Measuring the existing denture

Fig. 3: Tissue stops with retractors in place

taught in school) and the stone should be mixed with a Vacuumixer after carefully weighing out and measuring the stone and water. If you have the equipment in your office to do so, I would highly recommend this material. If you do not have the capabilities of following this protocol, then I would consider using VPS as your impression material and allowing the lab to pour the models.

Polyvinyl Siloxane (VPS) – (Virtual XD; Ivoclar Vivadent) – can be used to “customize” your impression tray and provide an excellent retentive impression. Of your hour-long initial visit, expect to spend roughly 45 minutes on the following impression technique. Your initial step in the impression technique is to select the proper tray size. If the patient is currently edentulous, use the existing denture to measure the distance between the maxillary tuberosities with a measuring gauge (Fig. 2). Use this measurement to select a tray that demonstrates the same position of the tuberosities. Make sure you verify the fit intra-orally prior to starting the impression. Retractors such as the “See More Retractors” (DENTSPLY) or “OpteraGate” (Ivoclar Vivadent) are used to aid in the impression-taking process and are removed following placement of the impression tray. Prior to each step, the retractors are repositioned (Fig. 3). Once selected, the second step in the process is to add “tissue

continued on page 66

stops" by injecting three small areas on the tray (bilaterally over the ridge and the hard palate) with heavy body impression material (Fig 3). Allow this to set fully prior to removal.

Next, start the border molding process. Once again, heavy body impression material is injected, starting from the side of the maxillary tuberosity and continuing to the canine area. Care is given to avoid having impression material go behind the tuberosity into the hamular notch area just yet (Fig. 4). Place the impression tray, remove the retractors from the patient's mouth, and border mold this side of the impression by actively moving the patient's cheek in an anterior, posterior and downward motion (Fig. 5). Continue the border molding process by next border molding the anterior segment only (Fig. 6), and then the opposite side, taking action to activate the labial frenum in the anterior and posterior regions each time.

Once the border molding is complete, inspect the tray for areas of show-through. Adjust these areas with an acrylic bur to remove the over-extended areas or areas of the tray on the internal aspect that show through the impression. Complete the impression by adding light body impression material to the tray and placing it into the patient's mouth, starting with the posterior segment and seating toward the anterior. Repeat the border molding process on both sides bilaterally, then the anterior segment. Finish the posterior palatal seal portion of the impression by first holding the patient's nose and asking them to blow hard

through it. Next, ask the patient to open as wide as possible, close half way down, and then repeat opening and closing a second time. This action will capture the hamular frenum in the light body impression material and is the reason why this area was not initially border molded with the heavy body material. Once set, your maxillary impression is now complete (Fig. 8).

Repeat the same process for the lower denture by border molding the labial segments first and finishing off on the lingual. A trick to prevent the lower denture from dislodging in functional movements is to have the patient close against your fingers, stick the tongue out and move it from one corner of the lip to the other when bordering molding the lingual segments. This process should be repeated once you add the light body impression material to complete the full impression. This action will prevent over-extension onto the mylohyoid area, which can act as a sling when the denture covers it.

Step 2: Smile Design Tools

Once the impressions are completed, order a custom wax rim length by measuring the length of the maxillary lip and the current denture teeth set up. These steps take approximately five minutes of extra time on the initial visit but save a lot of time on your second visit from having to make large adjustments to a stock wax rim length. The instruments used for this are the papillameter (Fig. 9) and alma gauge (Fig. 10). The papillameter is placed

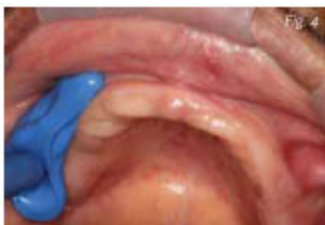

Fig 4

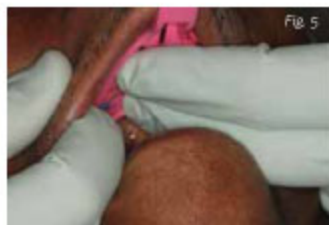

Fig 5

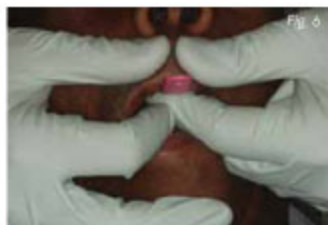

Fig 6

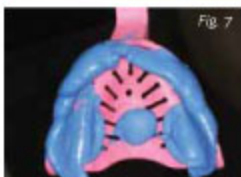

Fig 7

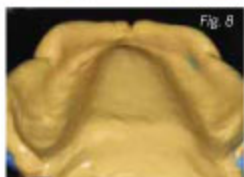


Fig 8



Fig 9



Fig 10

Fig 4: Border molding injection
Fig 5: Border molding action
Fig 6: Anterior border molding action
Fig 7: Border molding complete
Fig 8: Final impression
Fig 9: Papillameter
Fig 10: Alma gauge

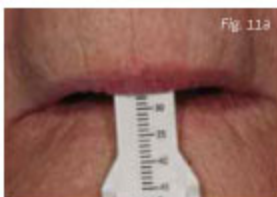

Fig. 11a

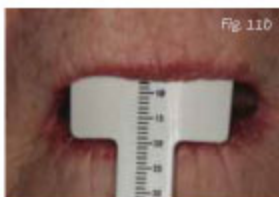

Fig. 11b



Fig. 12a



Fig. 12b



Fig. 13

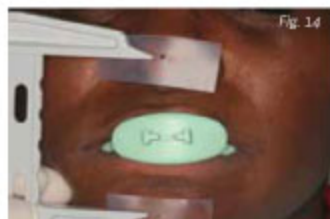

Fig. 14

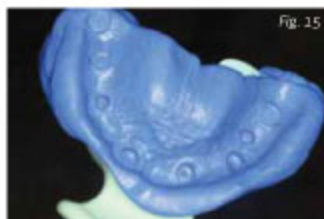


Fig. 15

under the patient's lip and against the incisive papilla, allowing you to accommodate for the varying maxillary lip lengths. The patient's lip is measured at rest to determine the proper vertical position of the wax rim (Figs. 11a & b). Discuss with the patient how much tooth structure the patient would like to display at rest; the measurement can be adjusted accordingly to fit the patient's needs. When ordering the wax rim, I suggest allowing for 1-2mm at rest.

The alma gauge allows you to measure both the vertical and horizontal position of the incisal edges from the incisive papilla of the existing denture. The existing denture can be judged for its cosmetic appearance. Wax or flowable composite can be added to the old denture as a "cosmetic mock-up" to test the appearance of the planned final denture. These new lengths can then be measured by placing the denture on the gauge and depressing the plunger into the dentures incisal papilla area. The vertical and horizontal measurements are recorded and transferred to the lab. This will become the length, as well as horizontal thickness, of the wax rim ordered.

The final 10 minutes of your first visit are to use the centric tray (Fig. 13) to record an arbitrary bite relationship in fully edentulous patients. This can be taken at the patient's existing VDO and will facilitate the lab in the proper mounting of the gothic arch tracer/centric recording device for your next visit. Gauze is used to line the centric tray to facilitate removal of the putty once the lab has mounted the study models. Putty is hand-mixed and placed inside the maxillary and mandibular components of the tray, and then placed in the patient's mouth while the patient is asked to close to a reasonable proximity of the existing denture VDO (Fig. 14). Once the putty is set, the impression is removed (Fig. 15) and sent to the lab with the full-arch impressions, papillameter, and alma gauge readings for design of the wax rim and initial smile design.

Fig. 11a: 22mm at rest lip length

Fig. 11b: 7.5mm at rest lip length

Fig. 12a: Vertical measurement

Fig. 12b: Horizontal measurement

Fig. 13: Centric tray

Fig. 14: VDO from existing dentures transferred to centric tray

Fig. 15: Completed centric tray

Second Appointment - Enhanced Wax Relations (approximately 30-45 minutes)

Since the wax rim should be near the perfect length and horizontal positions, this visit is significantly shorter and less involved than the traditional denture fabrication process. The time saved here in adjusting the wax rim allows us to record the patient's VDO and centric relation position with the use of the gothic arch tracer/centric recording device.

Step 1

The first step in this visit is to evaluate the wax rim length and make any necessary adjustments to the vertical and horizontal positions (Fig. 16). Marks are scribed into the wax rim for the lip at rest position, high smile line and midline (Fig. 17). The wax rim former (Fig. 18) is designed to facilitate the development of the occlusal plane once the desired incisal edge position has been achieved. Ensuring parallelism between the maxillary and mandibular rims is essential for a correct bite registration, if the gothic arch tracer is not to be used. When aligning the rims to Camper's plane, it is particularly important to be able to melt the rims uniformly. The ledge of the rim former fits precisely into the hamular notches on the maxillary cast. The hamular notches are always parallel to one another and to the midlevel of the face;^{4,5} it is important to have your base plate

4. J Prosthet Dent. 2002 Sep;107(3):174-6. Incisive papilla line as a guide to position maxillary anterior teeth properly. Gh FS, Hession C.

5. J Prosthet Dent. 2007 Oct;98(4):312-8. The three-dimensional relationship on a virtual model between the maxillary anterior teeth and incisive papilla. Park JS, Lee SH, Park KS.

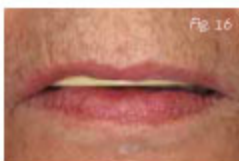

Fig. 16

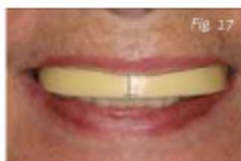

Fig. 17



Fig. 18

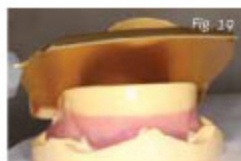

Fig. 19

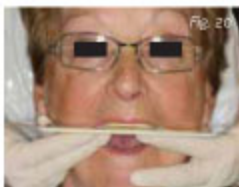

Fig. 20



Fig. 21

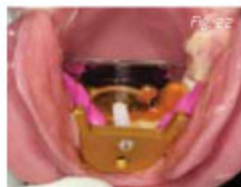

Fig. 22

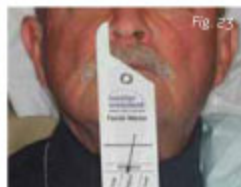

Fig. 23

impressions detailed enough and free of distortion in these areas. The 5mm ledge present on the rim former ensures that when the maxillary wax rim is melted down to the desired incisal edge position (chosen by using the papillameter and marked on the wax rim) (Fig. 19), the occlusal plane will be uniform on both right and left sides and should be parallel to Camper's plane. Typically, I use the lower base plate to record the incisal edge position of the mandibular teeth equal to the lower lip line at rest.

Step 2

The second step of this visit is to confirm that the wax rim is parallel to the patient's interpupillary line and that a cant does not exist. This can be accomplished two ways. The first is to use the occlusal plane that is present in the Smile Design Kit (Fig. 20). The second is to use a Kois Facial Analyzer. If the interpupillary line and horizontal plane do not match, you have the option of either correcting the wax rim or using VPS bite registration material on the occlusal plane to compensate for the irregularity. The VPS record should be sent with the wax rim to the lab for corrective mounting.

Step 3

The third step is to record the patient's vertical dimension of occlusion and centric relation position. The calipers in the Smile Design Kit (Fig. 14) can be used to replicate the same VDO as the patient's existing dentures or aid in selection of an increase. There are several gothic arch tracers/centric recorders on the market including the Gnathometer (Ivoclar Vivadent), Y&M Intraoral Tracer (Edmonds Dental Lab), Intra-Oral Establisher (Massad-Davis) or Coble Balancer to help record the patient's centric relation position. To facilitate in this process, it is sometimes easier to have the lab fabricate a second set of base plates with the recorder mounted on it without the wax rims. Recording the centric relation position is probably the single-most important step in denture construction, second only to the impression technique. It is ideal to first adjust the vertical component of the recorder to match the patient's desired VDO. Depending on what tracer you are using,

Fig. 16: Confirmation of wax rim length

Fig. 17: Incisal edge position, midline and high smile line indicated

Fig. 18: Wax rim former

Fig. 19: Wax rim former adjusting wax rim

Fig. 20: Occlusal plane

Fig. 21: Gothic arch tracer

Fig. 22: Completed gothic arch record

Fig. 23: Facial Meter

you may either want to paint the strike plate with magic marker or use articulating paper to mark the strike plate. (It is best to follow manufacturers instructions on which one would be best.)

Once properly marked, the patient is instructed to slide the mandible forward, backward, and into left and right lateral excursions. The resulting marks on the strike plate should resemble an arrow; the tip of this arrow is the patient's CR position (Fig. 21). The center of the centric pin receiver is then placed over the point of the arrow and luted to the strike plate with sticky wax or green stick compound. The base plate is then placed back in the patient's mouth and the patient is guided until the pin goes into the hole in the centric receiver. At this time, use hard bite registration material, Putar D (Kettenbach), to secure the baseplates together (Fig. 22).

Step 4

The last step on the wax-relations visit is to select the tooth size, mold and shade with the use of the Facial Meter (Fig. 23). The cosmetic outcome of your denture is highly reliant on tooth selection and custom processing of the denture base by your laboratory. Depending on your case fee, several denture tooth options present themselves from basic to premium in aesthetics and function. The Phonares II by Ivoclar Vivadent are an excellent option in the premium range. Tooth selection is facilitated by the interalar distance as measured by the Facial Meter. Teeth are offered in small, medium or large molds with choice of bold or soft forms, each offered in long or short for age appropriation.⁷ Typically, the posterior setup I most often use is Lingularized Balanced for the cosmetic appearances resembling natural teeth and the functional ease of equilibration.

Third Appointment – Wax Try-in (approximately 15-30 minutes)

With all the extra steps you have taken in the previous two visits, the “wax try-in” visit becomes a simple confirmation of the patient’s smile, occlusion and selection of processing shade. This visit gives the patient a chance to preview his or her smile and make any changes from the desired plan. Many patients today are selecting a Phonares II form and setup that allows for a more natural appearance. This can be accomplished with rotation of the lateral incisors, placing the premolars slightly off the facial plane from the canine to the molar, mimicking a slight decrease in the buccal corridor or angling one of the canines so more of the distal aspect of the tooth shows over the other. Rather than spending time making adjustments chairside, corrections are usually done so with photography to communicate the desired changes to the lab. However, if you prefer to make the changes chairside, scheduling a 30-minute try-in will ensure enough time to make any last-minute changes to the position of teeth as deemed necessary.

The final step in the denture process is to select the shade and type of processing for the lab to finish the denture. Ivoclar and the new Ivoclar pressed processing have long been established as the premiere processing for denture-base finishing. If you have been unhappy with the fit of your dentures, despite having a very retentive impression on your first visit, inaccuracy in processing maybe the cause of your problems. For this reason, I recommend you have a discussion with your lab as to whether it is utilizing a cold cure or pressed processing system. Once your processing shade has been chosen (Fig. 25), your dentures are ready for processing!

Delivery Day (approximately 30 minutes)

It is finally here, delivery day! It is normal to have to adjust the dentures for ease of insertion and removal. Once these sore spots are adjusted, the occlusion can be confirmed. The dentures should have simultaneous bilateral contact into closure, as well as have simultaneous contacts in excursions. As a rule of thumb, when the patient returns for post-op visits, adjustments are only made to the internal aspect of the denture if the patient states that

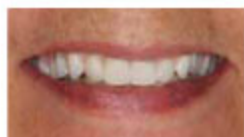

Fig. 24: Wax try-in



Fig. 25: Processing shade selector



Fig. 25: Post-op headshot

the offending area hurts during insertion or removal of the denture. Otherwise, if the denture does not hurt to insert or remove, but becomes sore after a period of use, the occlusion should be considered the cause.

Following this detailed protocol, I am sure you will find that your patients will be not only pleased with the cosmetic outcome of their prosthesis, but also require less post-insertion adjustments. Our population is aging and edentulism isn't going away, as we once thought it would. More and more patients are shying away from the coupon dentures that are available and are searching for dentists who can provide them with high quality prosthetics. Forget your bad experiences or what you learned in dental school! With a streamlined, tried-and-true system, dentures can be fun, rewarding and profitable! ■

References

1. *J Prosthodont*. 2008 Oct;17(7):372-5. *Igub*. 2008 Aug 28. Occlusal plane orientation: a statistical and clinical analysis in different clinical situations. *Agarwal* S, *Rasochandran* CB, *Varghese* B.
2. *J Oral Rehabil*. 2007 Feb;34(2):136-40. *Three-dimensional analysis of the occlusal plane related to the basion-menton-papilla occlusal plane in young adults*. *Yu JS, Hong CC, Hong DC, Wang JC.*
3. *J Indian Dent Assoc*. 1984 Nov;38(11):425-8. *An investigation into the distance between incisive papilla and incisal edge of maxillary central incisor*. *Khawat DU, Madan BE.*
4. *J Appl Med Coll Abroad*. 2009 Oct-Dec;21(4):125-8. *Comparison of distance between maxillary central incisor and incisive papilla in denture individuals with different arch forms*. *Zia M, Akmal AA, Akmal S.*



Would you like to post a comment? Visit DentalTown.com/magazine.aspx. Read. Learn. Comment. Enjoy!



Author's Bio

Dr. John Nosti practices full time in Mays Landing/Somers Point, New Jersey, as well as Manhattan, New York, with an emphasis on functional cosmetics, full-mouth rehabilitations and TMJ dysfunction. Dr. Nosti is the Clinical Director for The Clinical Mastery Series, a continuum geared toward advancing the cosmetic/functional practices of dentists worldwide. He is a member of the American Dental Association, American Academy of Cosmetic Dentistry, American Academy of Craniofacial Pain, American Academy of Dental Sleep Medicine and the Crown Council. Dr. Nosti also holds fellowships in the Academy of General Dentistry, the Academy of Comprehensive Esthetics, and the International Congress of Oral Implantologists.

